

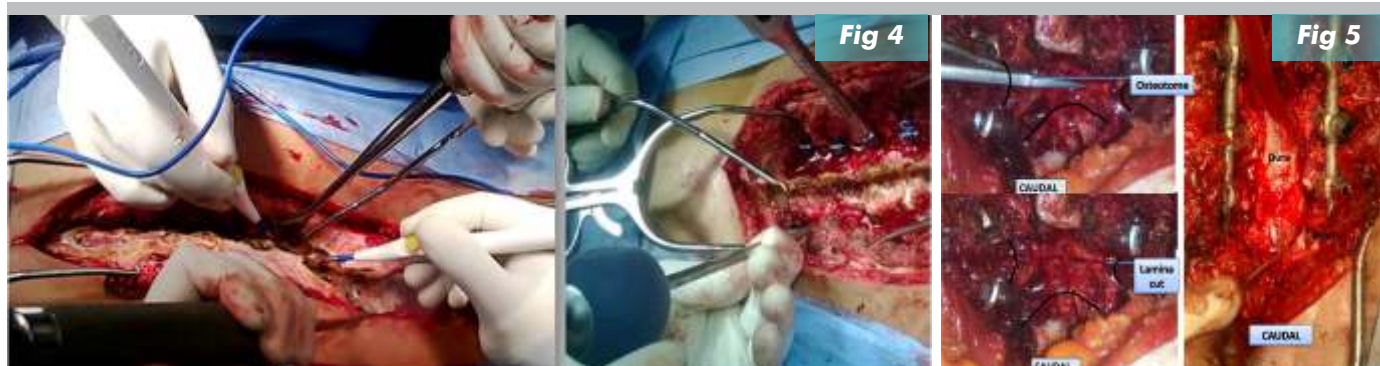Fig 4
Intra-operative photograph showing simultaneous bilateral posterior subperiosteal exposure and simultaneous pedicle screw insertion by free hand technique

Fig 5
Intraoperative photographs showing laminectomy technique with use of osteotome on the left side, and the decompressed dura with the roots at the end of the procedure.

We are glad to bring to your notice that with a team approach and specific techniques adapted at our institute, like simultaneous bilateral exposure, free hand pedicle screw insertion (Lumbar - Lenke et al³ Cervical - Mahesh et al²) and the osteotomy technique for decompression (Practice in Korea and Japan⁴, but not much in the west), over a period of time we have been able to achieve consistently good results with lesser rates of complications in elderly patients, as compared to literature published from the west. The above study from our institute is in the process of being published.

REFERENCES

1. Mirza SK, Deyo RA, Heagerty PJ, Konodi MA, Lee LA, Turner JA, Goodkin R. Development of an index to characterize the "invasiveness" of spine surgery: validation by comparison to blood loss and operative time. Spine (Phila Pa 1976). 2008 Nov 15; 33(24):2651
2. Mahesh B, Upendra B, Mahan RS. The medial cortical pedicle screw - a new technique for cervical pedicle screw placement with partial drilling of medial cortex. Spine J. 2014 Feb 1; 14(2):371-80. doi:10.1016/j.spinee.2013.09.033. Epub 2013 Oct 19.
3. Kim YJ, Lenke LG, Bridwell KH, Cho YS, Riew KD. Freehand pedicle screw placement in the thoracic spine: is it safe? Spine (Phila Pa 1976). 2004 Feb 1; 29(3):333-42
4. Okuda, Shinya, Takenori Oda, Akira Miyauchi, Takamitsu Haku, Tomio Yamamoto, and Motoki Iwasaki. "Surgical Outcomes of Posterior Lumbar Interbody Fusion in Elderly Patients. Surgical Technique." The Journal of Bone and Joint Surgery. American Volume 89 Suppl 2 Pt.2 (September 2007): 310-20. doi:10.2106/JBJS.G.00307.

Multilevel spine surgery in the elderly – Is it safe?

- With the increase in life expectancy, spinal disorders in the elderly are increasing, with compressive Myelopathy or radiculopathy curtailing the old and making many of them restricted to their beds.
- Spine surgery after the age of 60 is feared by patients and discouraged by most doctors due to the presumed high complication rates.
- Acceptability of surgery improves if operative morbidity in elderly patients requiring spine surgery is decreased.
- Operative time and blood loss have been proven¹ to be the two most significant factors associated with increased postoperative morbidity.
- Techniques to reduce operative time and blood loss will therefore decrease post-operative morbidity and make spine surgery safer in the elderly patients.

CASE REPORT 1

A 68 year lady had come to us with progressive difficulty in walking for 4-5 years (due to Neurogenic claudication) and inability to walk for more than few steps in the house for the last few months. The pain used to decrease with sitting and increased on standing. She also gave history of difficulty in holding on to her footwear for 1-2 months (Had ankle and toe weakness on examination). She had visited many doctors and had partial relief of pain initially, with physiotherapy and medications. However since 4-5 months her back and leg pains had become progressive, almost restricting her to the bed and she had also started developing weakness in her feet with progressive numbness. Her MRI and radiographs showed instability and spondylolisthesis at L4-5 and L5-S1 along with severe canal stenosis from L2 to S1 (Fig-1).

Dr. Mahesh B.H.

M.S. (Ortho) AIIMS, New Delhi
Spine Surgeon and
Head of Department

Dr. Upendra B.N.

M.S. (Ortho) AIIMS, New Delhi
Spine Surgeon

Dr. Anand Jayaraman

MRC Psych (UK)
Consultant Psychiatrist
& pain management

Dr. Vijay S.

M.S. (Ortho)
Spine Fellowship (CMC Vellore)
Spine Registrar

Dr. Arun Kumar G.C.

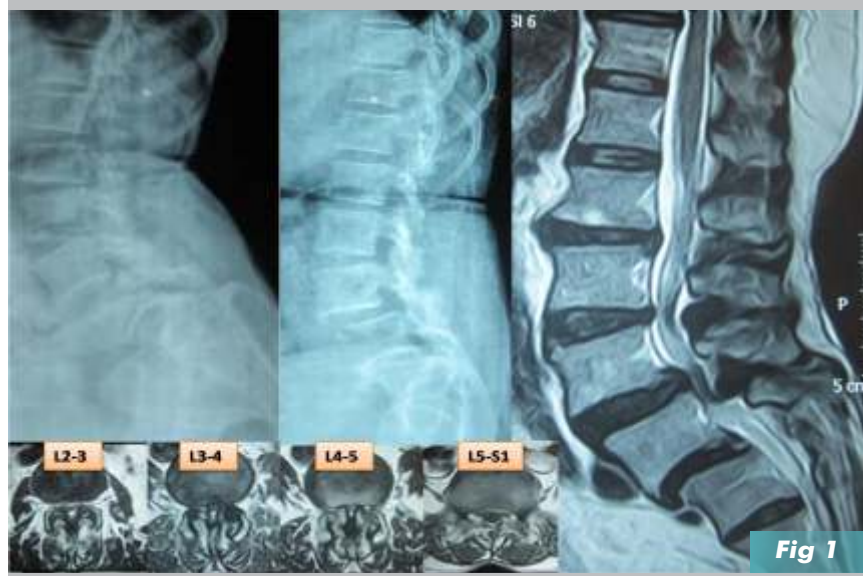M.S (Ortho)
Spine Registrar

Leena

Secretary & Co-ordinator

Gangadhar A.S.

Co-ordinator



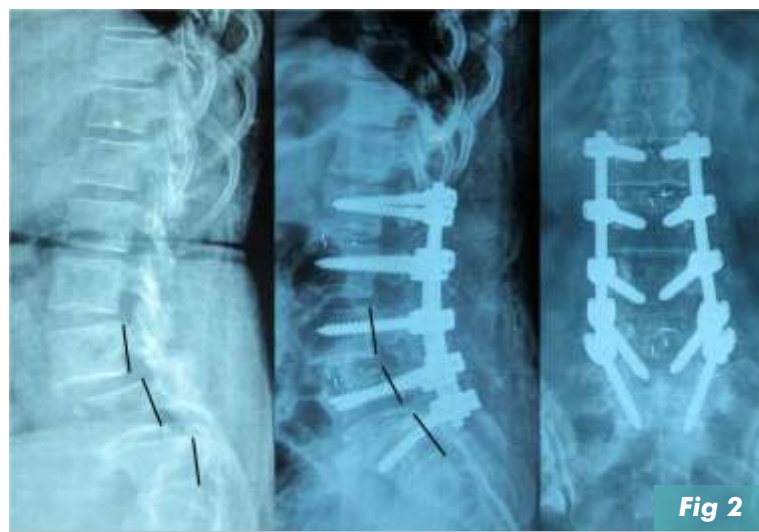
Preoperative radiographs showing spondylolisthesis and instability at multiple levels along with MRI picture showing severe stenosis from L2-3 to L5-S1 causing severe compression of cauda equina.

Patient Said -
"She was advised to somehow manage her daily activities"

Fig 1

Though many of the doctors had mentioned to her that she required decompression surgery for her spine, she was warned against the surgery due to the complications involved in undergoing extensive spinal decompression and instrumentation at her age. Therefore she was advised to somehow manage her daily activities. However, the condition had deteriorated rapidly with weakness and inability to carry her daily activities despite taking all medications.

She was offered decompression and spinal fixation with fusion at our institute. The patient, though apprehensive, was relieved to know that surgical decompression is possible. Her only nightmare was getting bed-ridden either because of the disease or due to surgical complication. After detailed counseling of the patient and relatives, explaining the possibility of further neurological damage with surgery being less than 1%, the patient agreed for surgery. She underwent posterior pedicle screw-rod instrumentation with L2 to L5 Laminectomy and bilateral facetectomy and interbody fusion. The patient recovered well and is under our follow up for the last 18 months. She is able to walk for about 2-3km without claudication.



Postoperative radiographs on the right showing realignment of the vertebrae in the sagittal plane, in comparison with the preoperative radiograph (Compare the dark lines on the posterior vertebral borders pre and postoperatively)

"Her only nightmare was of getting bed ridden either due to disease or surgery"

Fig 2

CASE REPORT 2

He was a 78 year old frail gentleman with progressive difficulty in walking due to compressive cervical Myelopathy with inability to walk for 6 weeks. In addition the patient had significant back pain with neurological claudication due to L4-5 spondylolisthesis and compression of the cauda equina.

Tandem Stenosis : He was an ideal example of what the scientific literature recognizes now as "Tandem Stenosis" requiring decompression at both cervical and lumbar levels. In addition to instrumentation for spondylolisthesis at lumbar level, the patient required stabilization of the cervical spine as well due to the kyphotic nature of the cervical spine and multilevel compression.

Cervical Pedicle Screws : With the advent of cervical pedicle screws, the cervical Kyphosis can now be corrected with posterior instrumentation alone with decompressive laminectomy and fusion. We have evolved and published² a modified free hand technique of cervical pedicle screw insertion with safer and easier placement of the screws. This enables an experienced surgical team to address both the cervical and lumbar surgeries in the same sitting.

Morbidity : The main deterrents for a simultaneous surgery are the perioperative complications and the morbidity involved in prolonged anaesthesia. Today, it has been reliably established that if the length of the surgery and blood loss can be decreased, the perioperative complications will be minimized.

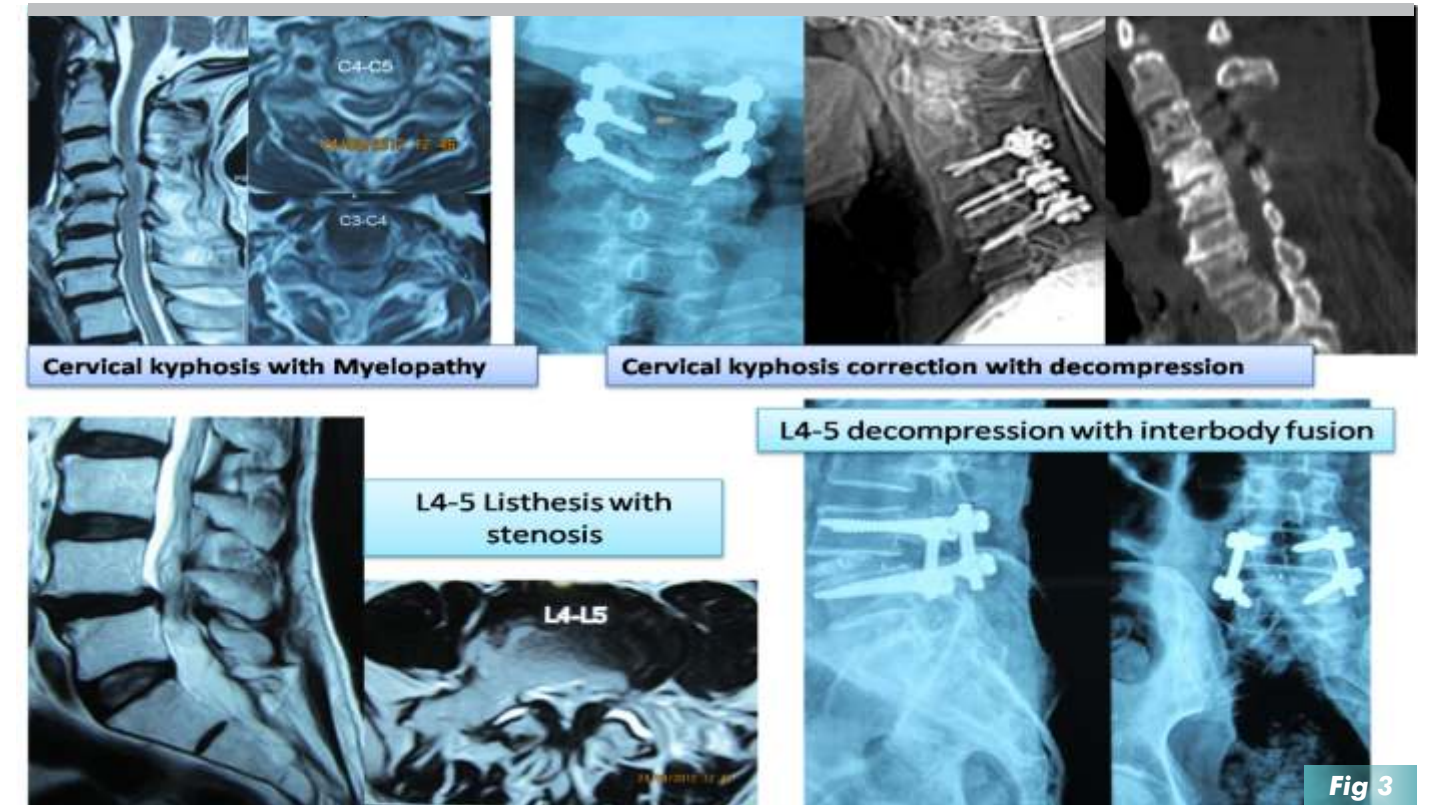


Fig 3: Shows simultaneous cervical and Lumbar surgeries done in 78 year old patient.

Fig 3

Preoperative work-up : The patient in addition to the age factor also had significant comorbidities with history of cerebrovascular accident, diabetes, hypertension and had undergone total laryngectomy for Ca Larynx 22 years ago. We, in consultation with the anaesthesia team, explained in detail the requirement for surgery and the risks involved in it due to the complexity of the surgery and issues involved in addressing both surgeries in a single stage. The fact that the patient's son himself was an anesthetist practicing abroad helped us to convey the realistic expectations out of the surgery and the advantage of performing both the surgeries at a single setting with a team approach.

Surgery : We successfully performed a simultaneous surgery on this patient with C3-C4 Laminectomy and C3 to C5 Pedicle screws fixation screw fixation + L4-L5 decompression and Transforaminal Lumbar Interbody fusion under GA. Both the surgeries were completed in five hours time with a team approach with about 550 ml of blood loss intra-operatively. The anaesthesia team had a tough job in administering anaesthesia for this patient and maintaining him under GA for 5 hours of the surgery. The patient did well postoperatively with no ICU care requirement and no major postoperative complications. His pre and postoperative images are shown below. His neurology improved marginally and was able to walk with walker after a week of surgery. The patient had further neurological improvement and was ambulatory with a stick till he succumbed to a silent Myocardial infarction, 28 months after the surgery.

Psychiatric issues in the elderly : We were surprised to know the extent of psychological and psychiatric problems faced by the elderly, along with the spinal disorders. We have a qualified psychiatrist (Dr.Anand Jayaraman) in our team who evaluates all the patients undergoing spine surgery pre and postoperatively for underlying psychiatric problems. Simultaneous treatment of the psychiatric problems along with spine surgery enhances the confidence of the elderly patients and adds to better functional outcomes. The case of an elderly man developing Ganser's syndrome, postoperatively, which was picked up and treated promptly, shows the immense value of the psychiatrist in our team. Other common psychiatric problems faced in the elderly in the short term are stress and anxiety syndromes, and long term problems like mild cognitive impairment (MCI) progressing to dementia.

Mild cognitive impairment (MCI) starts with early signs of memory loss. People with MCI are three to four times more likely to develop Alzheimer's disease and the risk of progressing to dementia is around 6% to 25% annually. (frequency of dementia doubles every 5 years after the age of 60 years). Alzheimer's disease, accounting for 60–80% of dementia is the most common form of MCI. Using the Hindi Mental State Examination (HMSE) or modified Mini-Mental State Examination (MMSE) had a varying response from 3.5% in Himachal Pradesh to 5.1% in Uttar Pradesh and 6.5% in Kashmir. A study in Kerala, south India, found the prevalence of cognitive impairment to be 11.5% in those aged >65 years.

Though we were fortunate to have good results in the above patients, not all of the elderly patients undergoing spine surgery do so well. The following are the results of a consecutive series of elderly patients who underwent spinal decompression and fusion surgery at our institute with documentation of operative and blood loss along with peri-operative morbidity and complications in the last 2 years.

Analysis of our surgical log books revealed a total of 55 consecutive patients, with age over 60 years, who were operated for spinal stenosis and instabilities with decompression and multilevel lumbar fusions in the last 2 year period. 49 patients were operated under general anaesthesia while the remaining 6 patients were operated in regional or spinal anaesthesia. Common indications for surgery were spondylolisthesis in 17(30.9%) and lumbar canal stenosis in 16 (29.1%) patients.

Table 1

Complications in the study group of 55 elderly patients who underwent multilevel spine surgery at our institute.

ICU	3 (5.4%)
Death (Chest infection and septicemia)	1 (1.8%)
Complications	No. of Patients
Dural Leak	3
Transient Root Deficits	2
Persistent Radicular Pain	2
Psychiatric (Ganser Syndrome)	1
Post Operative Infection	1
Chest Infection	2
Total	11 (20%)

A total of 11 complications were noted, 3 systemic and 8 local. Among the systemic complications 2 were chest infections and 1 was a psychiatric illness called Ganser's syndrome. All the 3 patients required transfer to ICU and 1 patient with chest infection expired due to septicemia and shock.

On comparing the complication rates with other variables we found that the patients with complications had higher blood loss, operative time, no. of instrumented levels and no. of interbody fusion levels. On analyzing these results statistically by ANOVA, the association of blood loss with complications was found to be statistically significant with p value of 0.002. The duration of stay, operative time and no. of interbody fusion levels were close to significance with p value of 0.63, 0.58 and 0.61 respectively (Table 2).

Table 2

Statistical analysis showing significant association between blood loss and complications

	Duration of Stay (Days)	Blood Loss (ML)	Operative Time (Mins)	No. of IB Fusions	No. of Instrumented Levels
No. Complication (N 44)	6.00	336.09	144.11	1.53	3.54
Complications (n-11)	7.67	550.00	180.00	2.00	4.11
P Value by ANOVA	0.063	0.002	0.058	0.061	0.318

In comparison with the published reports of spine surgery in the elderly, our study has an overall complication rate of 20% which closely follows the results published by Sakaura et al (Table 3). Also note that the average operative time and blood loss are more in the western literature (Frank et al, Michael et al and Ryan et al). Therefore, the most important factor decreasing the complication rate in our study and the Japanese study (Sakaura et al) is the lesser operative time, which automatically translates into lower operative blood loss.

Table 3

Shows the complication rates in relation to blood loss, operative time and associated co-morbidities published in literature in comparison to our study

Author	Sample size	Average age (range)	% co-morbidities	perioperative Complication rate	Specific complications	Operative time	Blood loss
Frank	21	77 (75-83)	72%	62% overall	38% major, 43% minor	415 ± 253 min (range 99-839 min).	1104 ± 848 ml (range 200-6100 ml)
Michael	46	66.8 ± 6.2	78%	37% overall 24% intraoperative	20% major, dural tear (7%), iliac vein tear (11%), misplaced pedicle screw (3%), and nerve root injury (3%), Death-4%, infection-(4%)	10 hours (range, 4-18)	2806 ± 840 ml (range 900-8100 ml)
Ryan	35	56.3 ± 11.0	85%	49% overall	26% major, 31% minor, infection(11%)	519 ± 160	2735 ± 1928
Sakaura	20	68.3	--	30%	Screw malposition-5%, post op radical pain-10%, root deficits-10%, deep infection-5%	218 ± 49 mins (range 164-393 mins)	612 ± 424 ml (range 160-2000 ml)
Sakaura	97	67	--	12%	Screw malposition-3.3%, dural tear-4.3%, post op radical 1.1%, deep infection-2.2%	145 ± 32 min (range 82-232 mins)	206 ± 143 ml (range 30-649 ml)
Our study	55	69	100%	20%	Dural tear(5.4%), infection(1.8%), persistent radicular pain(1.8%), systemic(5.4%), root deficits(3.6%), transient root deficits(3.6%)	150 minutes (range 60-270 minutes)	367.45 ml (range 90-1050 ml)

On analyzing these data we had to ask ourselves the following

Is the surgical practice in our institute any different, given the lesser operative time and blood loss?

With the changing concept of techniques required for a safe surgery in the elderly, we at JISAR, have been practicing a combination of surgical measures which gives maximum importance on decreasing the operative time and blood loss, without compromising on desired surgical goal (Table 4).

Table 4

Intra-operative Surgical measures practiced at our institute to reduce intra-operative blood loss and operative time

Surgical step	Surgical Techniques	Advantage of the Technique
Posterior exposure of the spine	1. Strict sub-periosteal plane exposure with coagulation cautery 2. Simultaneous exposure on either side of the spine by two independent spine surgeons	1. Decrease in blood loss 2. Decrease in time of exposure, especially in multilevel surgeries
Pedicle screw instrumentation	1. Free hand technique for thoraco-lumbar pedicle screw insertion without c-arm assistance (Lenke et al ³). Cervical pedicle screw free hand technique has been described from our institute (Mahesh et al ²) 2. Single lateral c-arm view for evaluating screw placement.	1. Significant reduction of operative time 2. Significantly decreased radiation hazard
Decompression	1. Laminectomy with osteotomes (Fig 5) – otherwise usually done with Kerrison rongers or burrs Few centers in Korea and Japan practice this technique ⁴	1. Significant reduction in operative time 2. Decreased chances of dural tears 3. Osteotomy decreases the chances of further neural compression with insertion of rongers in a tight canal
Interbody Fusion with end plate preparation	1. Specialized instruments and curettes for thorough and easy removal of disc material and end plates The specialized instrumentation is provided by few companies.	1. Moderate reduction in operative time 2. Thorough end plate removal enhancing the chances of good spinal interbody fusion.